

Howard University College of Dentistry

INTRODUCTION

- The primary objective of this review is to assess methods to treat dental complications in people with Sickle Cell Disease (SCD)
- Sickle Cell Disease (SCD) is a genetic disorder most prominent within ethnic groups such as African-American, Hispanic-American, Middle Eastern, and Afro-Caribbean communities.
- Sickle cell is an hemoglobinopathy in which a mutation occurs in the translation process of the Hbs gene on chromosome II, eventually leading to a structural deformation in red blood cells resulting in a sickle cell shaped red blood cells
- The sickle shaped red blood cells lead to many complications that affect different body systems including but not limited to stroke, eye problems, infections and episodes of pain or a painful crisis.

EFFICACY OF MEDICAL CONSULTATION (METHODS)

- Dental health professionals treating sickle patients should consult with a medical professionals prior to extensive dental procedures.
- The medical consult should reveal the complete health status of a patient, and lab values should be included as well. These complete health status reports should include information delineating which organ systems are affected by the patients sickle cell.
- Medical consults are not only advantageous towards ensuring successful and efficient dental procedures, but they are also beneficial towards ensuring and protecting the patient's overall well-being. Possible complications sickle cell patients may suffer during a dental procedure include but are not limited to: Serious infections, dental caries, increased risk of periodontal disease, slow healing, prolonged bleeding, extensive loss of teeth, etc.
- Medical consultations assist with minimizing post treatment complications when precise information regarding the patient's health status is communicated to the dentist prior to a dental procedure to initiate appropriate planning and execution.

MEDICAL CONSULTATIONS

- Prior to dental procedures, the dentist must also provide information to the patient's physician detailing the procedures being performed in order to predict possible effects of said procedure.
- Vital information such as the extensiveness and type of surgery, number and type of extractions, removal of exostoses and complex surgical periodontal procedures, type of anesthesia should be sent to the patient's physician so they can have proper and full understanding of the dental procedure being administered to their patient
- Sending information to the patient's physicians allows the patients physician to double check for any medication interactions that may be contradictory to the patients overall well being, and what symptoms their patients may present with after the procedure
- The patient's dentist should obtain detailed information regarding the patient's infusion medication injury as this may affect the patients: oropharyngeal pain, joint and muscle pain, fatigue, pruritus, urticaria, sweating, and possibly shortness of breath.
- If a dentist decided to go the extra step in ensuring their patients safety, they may also consult with the patient's hematologist.

COMMON DENTAL FINDINGS

- Oral manifestations in sickle cell patient tend to present as mucosal pallor, delayed eruption of teeth, and hypomineralization of dentin
- Researchers and their findings:
 - Soni reported hypomineralization of dentin, abrupt alterations of dentinogenesis, and hypercementosis in a small group of subjects with sickle cell disease.
 - Andrews reported five patients who exhibited osseous changes in teeth without pathogenesis.
 - Patton and Shroyer reported osteomyelitis of the mandible following sickle-cell crises.

RADIOGRAPHIC FEATURES OF SICKLE CELL DISEASE (SCD)

- The radiographic features in Sickle Cell Disease (SCD) have numerous causes.
- The bony changes in the cancellous bone depend on the extent of the hyperplasia of the bone marrow.
- The various changes evident in imaging such as changes in the trabecular pattern of the bone, including loss of fine trabeculae and formation of the bone marrow spaces.
- The thinning of the cancellous and cortical bone in the skull, vertebral bodies, long bone, and in the oral and maxillofacial bones,
- There is also evidence of the expansion of the frontal and parietal bones.

EFFECTS ON THE SKELETON

- The skull radiographs of a sickle cell disease patients show a widening of the diploic space, thinning of outer and thinner cortices, vertical trabeculations which are usually known as hair-on-end appearance, and granular appearance of the skull. But these changes are not specific findings to Sickle Cell Disease. These are also noted in other diseases and conditions such as thalassemia major, hereditary spherocytosis, and iron deficiency.
- There are small areas of infarction that may be present within bones due to microvasculature blockage, and it appears as localized bone sclerosis in the radiographs.

EFFECTS ON THE ORO-FACIAL BONES

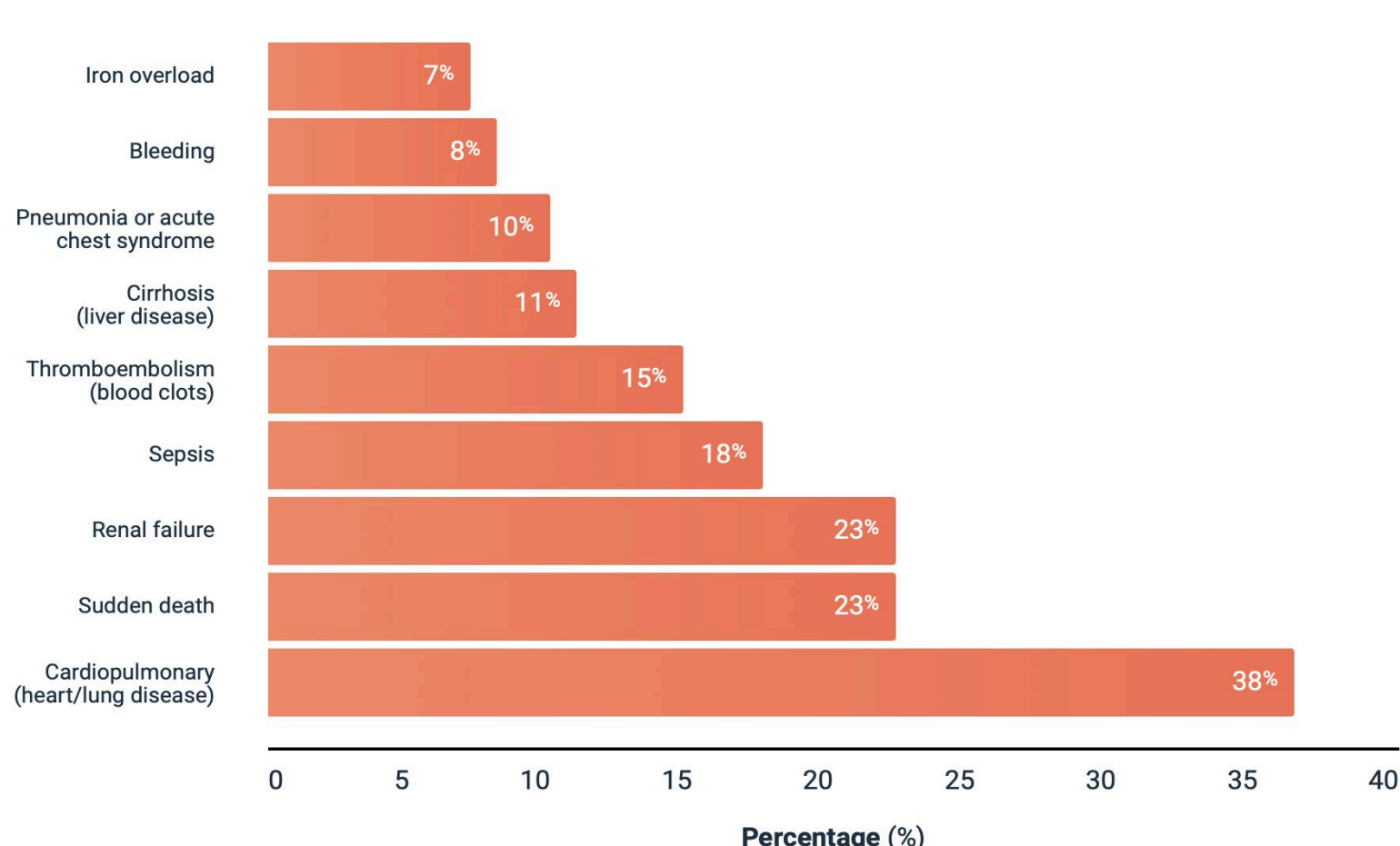
- Sickle cell anemia manifests as generalized osteopenia in the maxilla and mandible, more evident in the mandible.
- The radiographic appearance of the bone is irregular and dissipated inferior border of the mandible.
- The osteopenia is due to a decrease in the volume of trabecular bone.
- There is a slight thinning of the cortical plates as well.
- In most patients, the change is mild or moderate; extreme change is unusual in the jaws.
- Radiographs of pediatric patients with sickle cell anemia show a high frequency of severe osteopenia.
- The bone pattern may be altered to one with fewer but coarser trabeculae; Enlargement and protrusion of the maxillary sinus noted in SCD patients may be due to the bone marrow hyperplasia of the maxillary sinus.

EFFECTS ON THE TEETH

- There is evidence of developmental enamel hypomineralization and hypoplasia, which can affect enamel translucency and may be seen radiographically.
- Microradiography study conducted by Soni on the dental tissues of SCD patients revealed diffused hypomineralized zones in tooth enamel.
- The study also found unusual inclusions in the lumens of the dentinal tubules and pulp chambers that contain denticle-like calcified bodies.

TRENDS

COMMON CAUSES OF MORTALITY IN PATIENTS WITH SCD¹¹



CONCLUSION

- Abnormal bone is frequently seen in sickle cell disease and occurs from vascular occlusion.
- Pain in the jaw was thought to be secondary to the occlusion of the microvasculature.
- Severe osteopenia and pain in other parts of the body are reported in areas where microvasculature is included such as the head of the femur.
- The radiolucent areas are secondary to extreme medullary hematopoiesis, which is also common in sickle cell disease. Some sclerotic areas may not be subject to biopsy, as to not introduce bacteria into bony areas that could be susceptible to osteomyelitis.
- Treatment: Other than management of pain by analgesics, further definitive treatment required, patients are followed for ominous clinical and radiographic changes, such as expansion of the mandible or root resorption.